CLINICAL PRACTICE

Caren G. Solomon, M.D., M.P.H., *Editor*

Degenerative Rotator-Cuff Disorders

Nitin B. Jain, M.D., M.S.P.H., and Michael S. Khazzam, M.D.

This Journal *feature begins with a case vignette highlighting a common clinical problem. Evidence supporting various strategies is then presented, followed by a review of formal guidelines, when they exist. The article ends with the authors' clinical recommendations.*

A 55-year-old woman presents with 6 months of worsening right lateral shoulder pain. The pain wakes her from sleep and is worse when she reaches over her head or behind her back, such as when putting on a blouse. She had no preceding trauma. She works at a desk job. On physical examination, she has tenderness over the biceps and the coracoid process, painful arc of motion, weakness with manual muscle-strength testing (especially in the empty-can position, when testing the supraspinatus in the plane of the scapula), and a negative scapular retraction maneuver (indicating continued weakness of the supraspinatus with retraction and support of the scapula). How should this patient be further evaluated and treated?

From the Department of Physical Medicine and Rehabilitation, University of Michigan Medical School, Ann Arbor (N.B.J.); and the Department of Orthopedics, University of Texas Southwestern, Dallas (N.B.J., M.S.K.). Dr. Jain can be contacted at jainnb@med.umich.edu or at the Department of Physical Medicine and Rehabilitation, University of Michigan, 325 E. Eisenhower Pkwy., Suite 200, Ann Arbor, MI 48108.

N Engl J Med 2024;391:2027-34.
DOI: 10.1056/NEJMcp1909797
Copyright © 2024 Massachusetts Medical Society.

CME

THE CLINICAL PROBLEM

Shoulder symptoms led to an estimated average of 9.6 million ambulatory physician visits annually in 2015 and 2016 in the United States.[1] The incidence of surgery for rotator-cuff disorder, the most common cause of shoulder pain, across U.S. states ranges from 12 to 185 per 100,000 persons, with marked geographic variation.[2] Rotator-cuff disorder encompasses a spectrum of tendon degeneration, including (in order of increasing severity) rotator-cuff tendinopathy, partial-thickness tears, full-thickness tears, and rotator-cuff–tear arthropathy (a chronic rotator-cuff tear that leads to superior migration of the humeral head and arthritis over time). The rotator cuff comprises four tendons: supraspinatus (assists with abduction of the arm), infraspinatus (assists with external rotation of the arm), subscapularis (assists with internal rotation), and teres minor (assists with external rotation) (Fig. 1).

Tears of the rotator cuff can result from substantial traumatic injury (e.g., a motor vehicle accident, assault, a blow from a fast-moving projectile, or a fall from greater than standing height[3]) or can occur insidiously (atraumatic or degenerative rotator-cuff tear). Most degenerative tears, which are the focus of this review, occur in adults 40 years of age or older, and their prevalence increases with advancing age.[4] Other reported risk factors include male sex, a history of smoking, a history of heavy manual labor, coexisting conditions leading to vascular insufficiency (e.g., hypertension, diabetes, obesity, and hypercholesterolemia), and a family history of rotator-cuff tears.[4-8] Certain alleles are associated with a higher risk of rotator-cuff tears, which suggests a genetic predisposition.[5] Rotator-cuff tears are more common in the dominant arm.

In natural-history studies of degenerative rotator-cuff tears, at 5 years of follow-up, the tears were enlarged in half the persons with full-thickness tears,[9] and the

The New England Journal of Medicine is produced by NEJM Group, a division of the Massachusetts Medical Society.
Downloaded from nejm.org at Zhejiang University on November 28, 2024. For personal use only.
No other uses without permission. Copyright © 2024 Massachusetts Medical Society. All rights reserved.

KEY POINTS

DEGENERATIVE ROTATOR-CUFF DISORDERS

- Most rotator-cuff tears are degenerative and atraumatic and occur in adults 40 years of age and older, with the prevalence increasing with age.
- Rotator-cuff tears may enlarge over time, but there is a lack of correlation between patient symptoms and the size and thickness of the tear on imaging.
- Nonoperative treatment, including physical therapy, is typically the initial approach. Surgery is considered in selected patients whose rotator-cuff tears do not resolve with nonoperative treatment.
- The precise indications for surgery are debated. Patients generally have good outcomes after nonoperative or operative treatments.

tears had progressed to full thickness in approximately one third of those with partial-thickness tears.[10] However, the magnitude of enlargement was small in these studies and its clinical significance is unclear, since the size and thickness of rotator-cuff tears are not strongly associated with shoulder pain and function.[11,12] Fatty infiltration of the rotator-cuff muscles is present in 37 to 45% of patients with chronic rotator-cuff tears[13-15] and is associated with worse treatment outcomes.

STRATEGIES AND EVIDENCE

EVALUATION

Patients with an atraumatic or degenerative rotator-cuff tear typically present with insidious onset of lateral shoulder pain, although tears may be asymptomatic. The pain may be worse at night, leading to sleep disturbances, and, depending on the tendon involved, may be exacerbated by overhead activities (e.g., reaching for a high shelf, in the case of a supraspinatus tear) or activities that involve reaching behind the back (e.g., toileting, putting on a shirt or coat, and brushing hair). There may be weakness of the arm when lifting above the shoulder level.

Physical examination of the shoulder in a patient presenting with a suspected rotator-cuff tear begins with inspection of the shoulder girdle to assess for muscle atrophy in the periscapular region, scapular posture (to assess scapular mechanics), shoulder asymmetry, and scars from previous surgery. Active range of motion and arm strength in abduction, forward flexion, and external-rotation planes are usually affected by

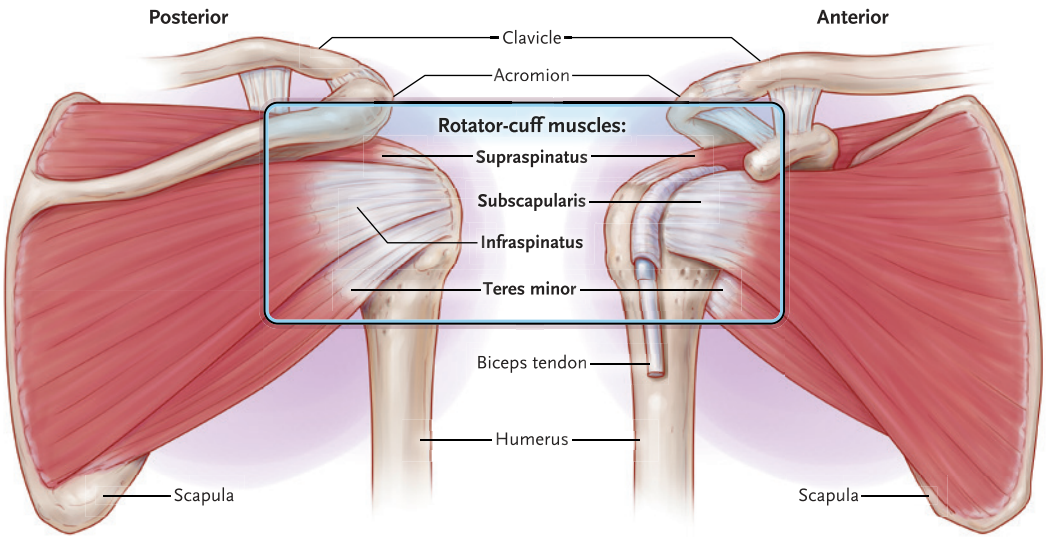

Figure 1. Normal Rotator-Cuff Tendons.

The New England Journal of Medicine is produced by NEJM Group, a division of the Massachusetts Medical Society.
Downloaded from nejm.org at Zhejiang University on November 28, 2024. For personal use only.
No other uses without permission. Copyright © 2024 Massachusetts Medical Society. All rights reserved.

tears and can be measured with the use of standardized protocols.[16] Passive range of motion may be normal but limited by pain. Several maneuvers have been described for making the diagnosis of a torn rotator cuff, but reported sensitivities and specificities vary widely.[17] (Videos 1 through 5 show some of these maneuvers.) A nomogram that was based on sex, results of lift-off and Jobe's (empty-can) tests, and external rotation strength was reported to predict the probability of a rotator-cuff tear in a patient presenting with shoulder pain,[18] although confirmation requires external validation (Fig. S1 in the Supplementary Appendix, available at NEJM.org).

Plain radiographs should include true anteroposterior, scapular Y, and axillary views. Although radiographs are not used to diagnose rotator-cuff tears, they can provide information on other potential sources of shoulder pain, such as osteoarthritis and dislocation. In very large chronic rotator-cuff tears, radiographic findings may include proximal humeral head migration, loss of the acromiohumeral interval, and superior glenoid wear. Ultrasonography and magnetic resonance imaging (MRI) of the shoulder can confirm rotator-cuff tears and provide information on size and location, tendon retraction, and muscle atrophy and fatty infiltration (Fig. 2). As compared with MRI, ultrasonography of the shoulder is relatively inexpensive and portable (can be performed at the point of care). Although the sensitivity and specificity of ultrasonography are similar to those of MRI for the diagnosis of full-thickness rotator-cuff tears,[19,20] it is operator-dependent. MRI has the advantage of better image quality and better definition of muscle tissue. The diagnostic accuracy of MRI and ultrasonography is lower for partial-thickness tears, and hence imaging in such cases should interpreted with caution. Because rotator-cuff tears may be incidentally found when MRI of the shoulder is performed for a different indication, routine imaging in primary care settings is not recommended. Ultrasonography or MRI of the shoulder may be useful in patients in whom a diagnosis is uncertain, a surgical intervention is potentially indicated, or information on tear extent or muscle degeneration is desired.

Videos showing maneuvers during shoulder examination are available at NEJM.org

TREATMENT

Although there is expert consensus that traumatic rotator-cuff tears should be treated operatively soon after the diagnosis is made to avoid long-term consequences such as rotator-cuff muscle degradation and tendon retraction,[21] most patients with symptomatic degenerative rotator-cuff disorders can be treated nonoperatively (Fig. 3). In cases in which a diagnosis of rotator-cuff tear can be made confidently in the primary care setting, physical therapy is an appropriate initial step. However, because recommendations regarding physical therapy and other treatment options are patient-specific and vary according to the cause of the shoulder pain, specialty referral

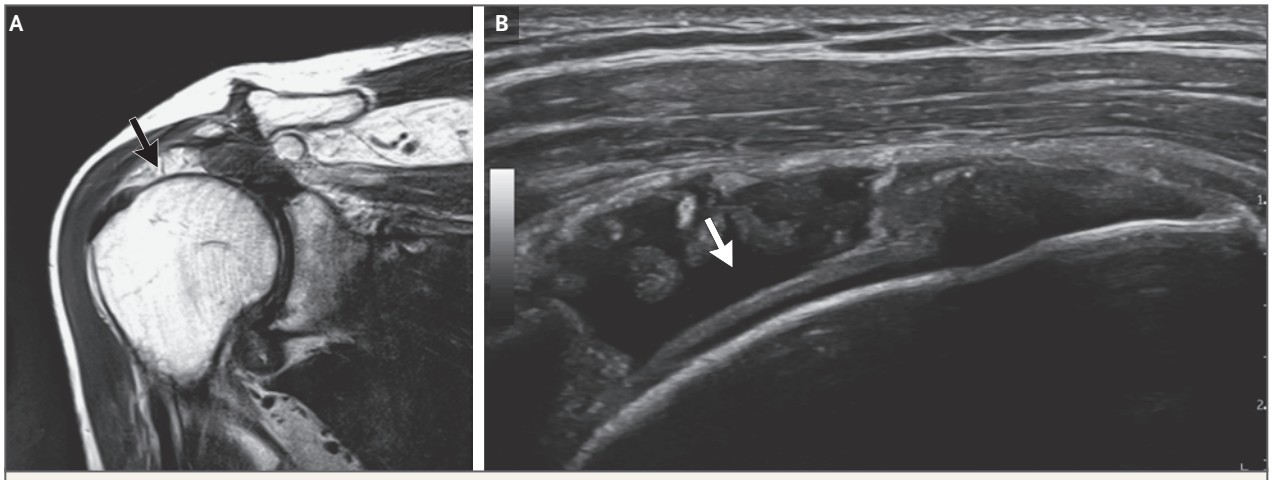

Figure 2. Magnetic Resonance Imaging and Ultrasonography of a Rotator-Cuff Tear.
Panel A shows T2-weighted magnetic resonance imaging of a full-thickness rotator-cuff tear, indicated by a hyperintense (bright) area (arrow). Panel B is a corresponding ultrasonogram of the rotator-cuff tear, indicated by a hypoechogenic (dark) area (arrow).

The New England Journal of Medicine is produced by NEJM Group, a division of the Massachusetts Medical Society.
Downloaded from nejm.org at Zhejiang University on November 28, 2024. For personal use only.
No other uses without permission. Copyright © 2024 Massachusetts Medical Society. All rights reserved.

(e.g., to a physiatrist [a physical medicine and rehabilitation specialist], rheumatologist, orthopedist, or sports-medicine specialist) should be considered, if available. Evaluation for psychosocial factors that may contribute to shoulder pain is also warranted.

Rehabilitation and Physical Therapy

Physical therapy is useful in the treatment of functional deficits in patients with rotator-cuff tears. It works by addressing periscapular muscle weakness, correcting scapular posture, and improving rotator-cuff muscle strength and endurance. In addition, the correction of deficits in the range of motion of the glenohumeral joint allows the shoulder to move through the full arc of motion, which decreases the work of the rotator-cuff musculature. A standardized, evidence-based physical therapy protocol is described in the Supplementary Appendix.

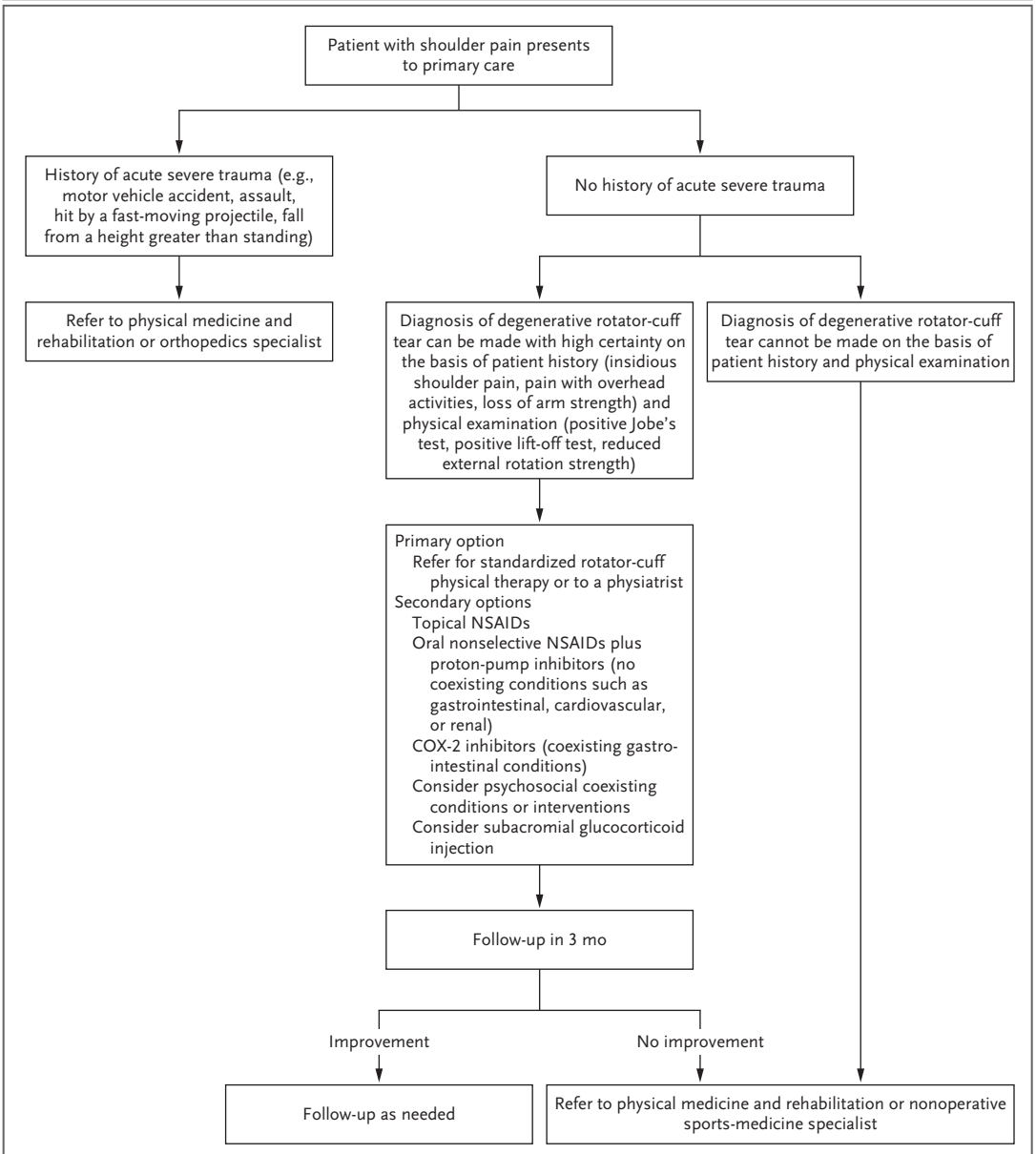

Figure 3. Management of a Suspected Rotator-Cuff Tear.
COX-2 denotes cyclooxygenase-2, and NSAIDs nonsteroidal antiinflammatory drugs.

The New England Journal of Medicine is produced by NEJM Group, a division of the Massachusetts Medical Society.
Downloaded from nejm.org at Zhejiang University on November 28, 2024. For personal use only.
No other uses without permission. Copyright © 2024 Massachusetts Medical Society. All rights reserved.

In observational studies, more than 80% of patients who received supervised physical therapy reported reduced pain and improved function at 6 months to 1 year of follow-up. In a small randomized trial comparing physical therapy with a sham intervention in patients with shoulder impingement (defined as a spectrum of shoulder conditions including, but not limited to, partial rotator-cuff tears), there were no significant differences between the trial groups with regard to pain and functional improvement at 11 weeks of follow-up, but the intervention group had greater improvement in shoulder function and strength at 22 weeks.[22] However, the trial population was heterogenous and there was no requirement for advanced imaging to confirm the diagnosis. Rigorous studies with adequate follow-up to assess the effectiveness of physical therapy as compared with sham therapy or no therapy in patients with rotator-cuff tears are lacking. In a prospective cohort study, factors associated with better outcomes after nonoperative treatment included being married, having at least a college education, shorter duration of symptoms, performing light or no manual labor in daily work, consuming alcohol 1 to 2 times or more per week, the presence of a partial-thickness tear, and the absence of fatty infiltration on imaging.[14] Among persons with full-thickness tears, the strongest predictor of successful physical therapy (i.e., avoidance of surgery) was high patient expectation regarding its effectiveness.[23]

Other Nonpharmacologic Therapy

Evidence suggests that psychosocial distress and depression are associated with shoulder pain and reduced function in patients with rotator-cuff tears.[24] Although data supporting psychosocial interventions in the treatment of rotator-cuff disorders are sparse, these interventions have shown benefit in the treatment of other musculoskeletal disorders.[25] Data from high-quality trials supporting the use of manual therapy, massage therapy, acupuncture, therapeutic ultrasonography, transcutaneous electrical nerve stimulation, shock-wave therapy, or pulsed-electromagnetic-field therapy are lacking.[26,27]

PHARMACOLOGIC THERAPY

Topical Medications

Topical nonsteroidal antiinflammatory drugs (NSAIDs) such as diclofenac and ketoprofen are effective in providing pain relief in chronic musculoskeletal pain and tendinitis and have a better safety profile than oral NSAIDs, although high-quality evidence supporting their specific use in rotator-cuff disorders is lacking.[28,29] Topical glyceryl trinitrate showed short-term benefit in the treatment of rotator-cuff disorders in a small randomized trial, but the risk of bias was considered to be high.[30]

Oral Medications

A meta-analysis of randomized clinical trials showed that oral NSAIDs reduced pain, although modestly, in patients with rotator-cuff disorders, a finding that is similar to the results of trials involving patients with other musculoskeletal conditions.[31,32] Adverse effects, including renal toxic effects, cardiovascular complications, and gastrointestinal bleeding, warrant caution in prescribing.[33,34] Although evidence specific to rotator-cuff disorders is not available, evidence exists supporting the use of nonselective NSAIDS with proton-pump inhibitors or cyclooxygenase-2 (COX-2) inhibitors in persons at increased risk for gastrointestinal bleeding.[35] Opioid drugs are generally not recommended owing to risks associated with their use and lack of evidence of superiority to nonopioid therapy in a variety of musculoskeletal conditions.[36] Acetaminophen has not been studied specifically in rotator-cuff disorders but has shown little or no benefit with regard to pain and function as compared with placebo in other musculoskeletal disorders.[37] Rigorous evidence is lacking to inform the use of pain-modulating drugs such as gabapentin, duloxetine, and pregabalin, specifically in regard to the nonoperative treatment of rotator-cuff disorders.

Glucocorticoid Injections

Injection of a glucocorticoid (together with a local anesthetic) has been reported to provide symptomatic pain relief in patients with rotator-cuff disorders, as compared with placebo.[38,39] Although clinical guidelines support the use of a single injection to provide short-term pain relief and improvement in function,[40] evidence is inconsistent and limited to small trials showing short-term benefit (for up to 4 weeks). These injections are performed subacromially, generally with the use of a palpation-based, landmark-guided approach; ultrasound guidance is used in some centers, although data are not available to

The New England Journal of Medicine is produced by NEJM Group, a division of the Massachusetts Medical Society.
Downloaded from nejm.org at Zhejiang University on November 28, 2024. For personal use only.
No other uses without permission. Copyright © 2024 Massachusetts Medical Society. All rights reserved.

support its superiority over a landmark-based approach.[41] Ultrasound guidance of these injections can reduce the risk of inadvertent injection into the tendon.

Biologic Therapies

Despite recent increases in the use of orthobiologic or regenerative-medicine therapies (such as platelet-rich plasma or stem cells derived from bone marrow or adipose tissue) in patients with rotator-cuff disorders, as well as some observational data that suggest improved outcomes, data from robust randomized, placebo-controlled trials supporting the effectiveness of these treatments are lacking. Thus, their use is not currently recommended for the treatment of rotator-cuff disorders.[42,43]

SURGERY

Surgery is not the initial recommended treatment in most patients with degenerative rotator-cuff tears, although surgery may be considered in some patients whose condition does not improve with conservative treatment. Consensus is lacking regarding indications for surgical intervention. Observational data support that surgery is associated with better function and reduced pain in patients who are younger (e.g., <65 years of age, although definitive age cutoffs are lacking), have smaller tears (e.g., <1.5 to 2 cm, although cutoffs vary), and have low fear-avoidance behavior (i.e., less tendency to catastrophize pain and avoid behaviors that might precipitate it).[15,44,45]

Surgery, which is most commonly performed arthroscopically, involves repairing the torn tendon and resecuring it to the humerus to allow for tendon-to-bone healing. Rotator-cuff surgery has a very low incidence of complications. Postoperative stiffness (generally responsive to physical therapy) occurs in approximately 10% of patients; complications such as deep-vein thrombosis and infection occur in less than 1%.[46,47] Acromioplasty is not routinely recommended[40,47] in rotator-cuff surgery, and no significant differences were observed between patients who underwent rotator-cuff surgery with biceps tenotomy or tenodesis (in which the long head of the biceps tendon is surgically incised or attached to the humeral shaft) and those who underwent surgery without either of these biceps procedures.[48]

A randomized trial comparing physiotherapy alone, physiotherapy plus acromioplasty, and the combination of rotator-cuff repair, acromioplasty, and physiotherapy for treatment of degenerative tears showed substantial improvements in all groups and no significant differences in a measure of pain and function at follow-up at 1 year and 2 years.[49,50] Another smaller trial of operative treatment as compared with nonoperative treatment (subacromial glucocorticoid injection, physiotherapy, and analgesic medication) in patients with degenerative tears showed no significant differences in function but significantly better scores on a visual-analogue scale at 1 year in favor of operative treatment.[51] In a meta-analysis of randomized trials involving patients with rotator-cuff disorder and subacromial shoulder pain, subacromial decompression was not superior to sham surgery (arthroscopy only) and is not recommended.[52]

AREAS OF UNCERTAINTY

The etiologic features of degenerative rotator-cuff disorders and their natural history — including factors that predispose tears to progression or to fatty infiltration — remain unclear. The clinical relevance of tear size and thickness is not clear; structural characteristics of rotator-cuff tears tend to correlate poorly with the severity of symptoms. Adequately powered randomized trials are needed to compare the outcomes of various treatment strategies, and more data are needed to better identify patient characteristics predictive of treatment success or failure.

The hypothesis that surgical intervention can reduce the progression of muscle degradation has led some experts to recommend early surgical intervention, but data are lacking with regard to outcomes of early surgery as compared with later surgery. Structural deficits of the rotator cuff are still observed at follow-up visits after rotator-cuff surgery despite good patient-reported outcomes[53]; this finding calls into question the basis of surgical tendon repair. Better understanding is needed of the biologic factors that lead to intrinsic tendon degeneration and how to address them, which might lead to better outcomes than are seen with currently available treatment approaches.[47,52]

The New England Journal of Medicine is produced by NEJM Group, a division of the Massachusetts Medical Society.
Downloaded from nejm.org at Zhejiang University on November 28, 2024. For personal use only.
No other uses without permission. Copyright © 2024 Massachusetts Medical Society. All rights reserved.

GUIDELINES

The American Academy of Orthopaedic Surgeons has published clinical practice guidelines for the management of rotator-cuff injuries that are primarily based on data from clinical trials.[40] The recommendations presented here are generally concordant with these guidelines.

CONCLUSIONS AND RECOMMENDATIONS

The patient described in the vignette has findings highly suggestive of a degenerative rotator-cuff tear. Additional history should address functional disability; psychosocial factors such as depression, anxiety, and coping mechanisms; and interference with sleep by pain. The physical examination should assess for supraspinatus involvement. We would refer the patient for a diagnostic ultrasonography of the shoulder (if available) if the diagnosis is uncertain, if a surgical intervention is potentially indicated, or if information on the extent of the tear or muscle degeneration is desired. Given the high likelihood of a degenerative rotator-cuff tear and expected improvement with nonoperative treatment, a referral to physical therapy and to a physiatrist would be appropriate. We would initially recommend a structured physical therapy program and consideration of treatment with a topical NSAID. If the patient's shoulder pain is expected to limit her ability to participate in physical therapy, a subacromial glucocorticoid injection, which can provide short-term relief, can be considered. The patient should be followed up for ongoing shoulder pain and functional disability. If there is inadequate improvement with physical therapy, referral to a physiatrist (if not already provided) or to an experienced orthopedist for consideration of surgical intervention is indicated.

Disclosure forms provided by the authors are available with the full text of this article at NEJM.org.

REFERENCES

1. Song A, Kim P, Ayers G, Jain N. Characteristics of non-spine musculoskeletal ambulatory care visits in the United States, 2009-2016. PM R 2021;13:443-52.
2. Jain NB, Peterson E, Ayers GD, Song A, Kuhn JE. US geographical variation in rates of shoulder and knee arthroscopy and association with orthopedist density. JAMA Netw Open 2019;2(12):e1917315.
3. Jain NB, Ayers GD, Koudelková H, et al. Operative vs nonoperative treatment for atraumatic rotator cuff tears: a trial protocol for the arthroscopic rotator cuff pragmatic randomized clinical trial. JAMA Netw Open 2019;2(8):e199050.
4. Teunis T, Lubberts B, Reilly BT, Ring D. A systematic review and pooled analysis of the prevalence of rotator cuff disease with increasing age. J Shoulder Elbow Surg 2014;23:1913-21.
5. Dabija DI, Gao C, Edwards TL, Kuhn JE, Jain NB. Genetic and familial predisposition to rotator cuff disease: a systematic review. J Shoulder Elbow Surg 2017; 26:1103-12.
6. Giri A, O'Hanlon D, Jain NB. Risk factors for rotator cuff disease: a systematic review and meta-analysis of diabetes, hypertension, and hyperlipidemia. Ann Phys Rehabil Med 2023;66:101631.
7. Grusky AZ, Giri A, O'Hanlon D, Jain NB. The relationship of aging and smoking with rotator cuff disease: a systematic review and meta-analysis. Am J Phys Med Rehabil 2022;101:331-40.
8. Park HB, Gwark J-Y, Im J-H, Jung J, Na J-B, Yoon CH. Factors associated with atraumatic posterosuperior rotator cuff tears. J Bone Joint Surg Am 2018;100: 1397-405.
9. Keener JD, Aleem AW, Chamberlain AM, Sefko J, Steger-May K. Factors associated with choice for surgery in newly symptomatic degenerative rotator cuff tears: a prospective cohort evaluation. J Shoulder Elbow Surg 2020;29:12-9.
10. Keener JD, Hsu JE, Steger-May K, Teefey SA, Chamberlain AM, Yamaguchi K. Patterns of tear progression for asymptomatic degenerative rotator cuff tears. J Shoulder Elbow Surg 2015;24:1845-51.
11. Curry EJ, Matzkin EE, Dong Y, Higgins LD, Katz JN, Jain NB. Structural characteristics are not associated with pain and function in rotator cuff tears: the ROW cohort study. Orthop J Sports Med 2015;3:2325967115584596.
12. Dunn WR, Kuhn JE, Sanders R, et al. Symptoms of pain do not correlate with rotator cuff tear severity: a cross-sectional study of 393 patients with a symptomatic atraumatic full-thickness rotator cuff tear. J Bone Joint Surg Am 2014;96:793-800.
13. Hebert-Davies J, Teefey SA, Steger-May K, et al. Progression of fatty muscle degeneration in atraumatic rotator cuff tears. J Bone Joint Surg Am 2017;99:832-9.
14. Jain NB, Ayers GD, Fan R, et al. Predictors of pain and functional outcomes after the nonoperative treatment of rotator cuff tears. Orthop J Sports Med 2018; 6:2325967118788531.
15. Jain NB, Ayers GD, Fan R, et al. Predictors of pain and functional outcomes after operative treatment for rotator cuff tears. J Shoulder Elbow Surg 2018;27: 1393-400.
16. Jain NB, Wilcox RB III, Katz JN, Higgins LD. Clinical examination of the rotator cuff. PM R 2013;5:45-56.
17. Jain NB, Luz J, Higgins LD, et al. The diagnostic accuracy of special tests for rotator cuff tear: the ROW cohort study. Am J Phys Med Rehabil 2017;96:176-83.
18. Jain NB, Fan R, Higgins LD, Kuhn JE, Ayers GD. Does my patient with shoulder pain have a rotator cuff tear? A predictive model from the ROW cohort. Orthop J Sports Med 2018;6:2325967118784897.
19. Lenza M, Buchbinder R, Takwoingi Y, Johnston RV, Hanchard NC, Faloppa F. Magnetic resonance imaging, magnetic resonance arthrography and ultrasonography for assessing rotator cuff tears in people with shoulder pain for whom surgery is being considered. Cochrane Database Syst Rev 2013;2013(9): CD009020.
20. Liu F, Dong J, Shen W-J, Kang Q, Zhou D, Xiong F. Detecting rotator cuff tears: a network meta-analysis of 144 diagnostic studies. Orthop J Sports Med 2020;8: 2325967119900356.
21. Pappou IP, Schmidt CC, Jarrett CD, Steen BM, Frankle MA. AAOS appropriate use criteria: optimizing the management of full-thickness rotator cuff tears. J Am Acad Orthop Surg 2013;21:772-5.

The New England Journal of Medicine is produced by NEJM Group, a division of the Massachusetts Medical Society.
Downloaded from nejm.org at Zhejiang University on November 28, 2024. For personal use only.
No other uses without permission. Copyright © 2024 Massachusetts Medical Society. All rights reserved.

22. Bennell K, Wee E, Coburn S, et al. Efficacy of standardised manual therapy and home exercise programme for chronic rotator cuff disease: randomised placebo controlled trial. BMJ 2010;340:c2756.
23. Dunn WR, Kuhn JE, Sanders R, et al. 2013 Neer Award: predictors of failure of nonoperative treatment of chronic, symptomatic, full-thickness rotator cuff tears. J Shoulder Elbow Surg 2016;25:1303-11.
24. Coronado RA, Seitz AL, Pelote E, Archer KR, Jain NB. Are psychosocial factors associated with patient-reported outcome measures in patients with rotator cuff tears? A systematic review. Clin Orthop Relat Res 2018;476:810-29.
25. Cherkin DC, Sherman KJ, Balderson BH, et al. Effect of mindfulness-based stress reduction vs cognitive behavioral therapy or usual care on back pain and functional limitations in adults with chronic low back pain: a randomized clinical trial. JAMA 2016;315:1240-9.
26. Page MJ, Green S, Mrocki MA, et al. Electrotherapy modalities for rotator cuff disease. Cochrane Database Syst Rev 2016;2016(6):CD012225.
27. Surace SJ, Deitch J, Johnston RV, Buchbinder R. Shock wave therapy for rotator cuff disease with or without calcification. Cochrane Database Syst Rev 2020;3(3):CD008962.
28. Derry S, Conaghan P, Da Silva JA, Wiffen PJ, Moore RA. Topical NSAIDs for chronic musculoskeletal pain in adults. Cochrane Database Syst Rev 2016;4(4):CD007400.
29. Mazières B, Rouanet S, Guillon Y, Scarsi C, Reiner V. Topical ketoprofen patch in the treatment of tendinitis: a randomized, double blind, placebo controlled study. J Rheumatol 2005;32:1563-70.
30. Cumpston M, Johnston RV, Wengier L, Buchbinder R. Topical glyceryl trinitrate for rotator cuff disease. Cochrane Database Syst Rev 2009;(3):CD006355.
31. Boudreault J, Desmeules F, Roy JS, Dionne C, Frémont P, Macdermid JC. The efficacy of oral non-steroidal anti-inflammatory drugs for rotator cuff tendinopathy: a systematic review and meta-analysis. J Rehabil Med 2014;46:294-306.
32. Enthoven WTM, Roelofs PD, Koes BW. NSAIDs for chronic low back pain. JAMA 2017;317:2327-8.
33. Nissen SE, Yeomans ND, Solomon DH, et al. Cardiovascular safety of celecoxib, naproxen, or ibuprofen for arthritis. N Engl J Med 2016;375:2519-29.
34. Perneger TV, Whelton PK, Klag MJ. Risk of kidney failure associated with the use of acetaminophen, aspirin, and nonsteroidal antiinflammatory drugs. N Engl J Med 1994;331:1675-9.
35. Bannuru RR, Osani MC, Vaysbrot EE, et al. OARSI guidelines for the non-surgical management of knee, hip, and polyarticular osteoarthritis. Osteoarthritis Cartilage 2019;27:1578-89.
36. Krebs EE, Gravely A, Nugent S, et al. Effect of opioid vs nonopioid medications on pain-related function in patients with chronic back pain or hip or knee osteoarthritis pain: the SPACE randomized clinical trial. JAMA 2018;319:872-82.
37. Saragiotto BT, Abdel Shaheed C, Maher CG. Paracetamol for pain in adults. BMJ 2019;367:l6693.
38. Arroll B, Goodyear-Smith F. Corticosteroid injections for painful shoulder: a meta-analysis. Br J Gen Pract 2005;55:224-8.
39. Buchbinder R, Green S, Youd JM. Corticosteroid injections for shoulder pain. Cochrane Database Syst Rev 2003;2003(1):CD004016.
40. American Academy of Orthopaedic Surgeons. Management of rotator cuff injuries: evidence-based clinical practice guideline. March 11, 2019 (https://www.aaos.org/globalassets/quality-and-practice-resources/rotator-cuff/rotator-cuff-cpg-final-12-20-19.pdf).
41. Ekeberg OM, Bautz-Holter E, Tveitå EK, Juel NG, Kvalheim S, Brox JI. Subacromial ultrasound guided or systemic steroid injection for rotator cuff disease: randomised double blind study. BMJ 2009;338:a3112.
42. Marks P, Gottlieb S. Balancing safety and innovation for cell-based regenerative medicine. N Engl J Med 2018;378:954-9.
43. van den Boom NAC, Winters M, Haisma HJ, Moen MH. Efficacy of stem cell therapy for tendon disorders: a systematic review. Orthop J Sports Med 2020;8:2325967120915857.
44. Keener JD, Patterson BM, Orvets N, Chamberlain AM. Degenerative rotator cuff tears: refining surgical indications based on natural history data. J Am Acad Orthop Surg 2019;27:156-65.
45. Lambers Heerspink FO, Dorrestijn O, van Raay JJ, Diercks RL. Specific patient-related prognostic factors for rotator cuff repair: a systematic review. J Shoulder Elbow Surg 2014;23:1073-80.
46. Brislin KJ, Field LD, Savoie FH III. Complications after arthroscopic rotator cuff repair. Arthroscopy 2007;23:124-8.
47. Karjalainen TV, Jain NB, Heikkinen J, Johnston RV, Page CM, Buchbinder R. Surgery for rotator cuff tears. Cochrane Database Syst Rev 2019;12(12):CD013502.
48. De Carli A, Vadalà A, Zanzotto E, et al. Reparable rotator cuff tears with concomitant long-head biceps lesions: tenotomy or tenotomy/tenodesis? Knee Surg Sports Traumatol Arthrosc 2012;20:2553-8.
49. Kukkonen J, Joukainen A, Lehtinen J, et al. Treatment of non-traumatic rotator cuff tears: a randomised controlled trial with one-year clinical results. Bone Joint J 2014;96-B:75-81.
50. Kukkonen J, Joukainen A, Lehtinen J, et al. Treatment of nontraumatic rotator cuff tears: a randomized controlled trial with two years of clinical and imaging follow-up. J Bone Joint Surg Am 2015;97:1729-37.
51. Lambers Heerspink FO, van Raay JJAM, Koorevaar RCT, et al. Comparing surgical repair with conservative treatment for degenerative rotator cuff tears: a randomized controlled trial. J Shoulder Elbow Surg 2015;24:1274-81.
52. Karjalainen TV, Jain NB, Page CM, et al. Subacromial decompression surgery for rotator cuff disease. Cochrane Database Syst Rev 2019;1(1):CD005619.
53. McCarron JA, Derwin KA, Bey MJ, et al. Failure with continuity in rotator cuff repair "healing". Am J Sports Med 2013;41:134-41.

Copyright © 2024 Massachusetts Medical Society.

The New England Journal of Medicine is produced by NEJM Group, a division of the Massachusetts Medical Society.
Downloaded from nejm.org at Zhejiang University on November 28, 2024. For personal use only.
No other uses without permission. Copyright © 2024 Massachusetts Medical Society. All rights reserved.